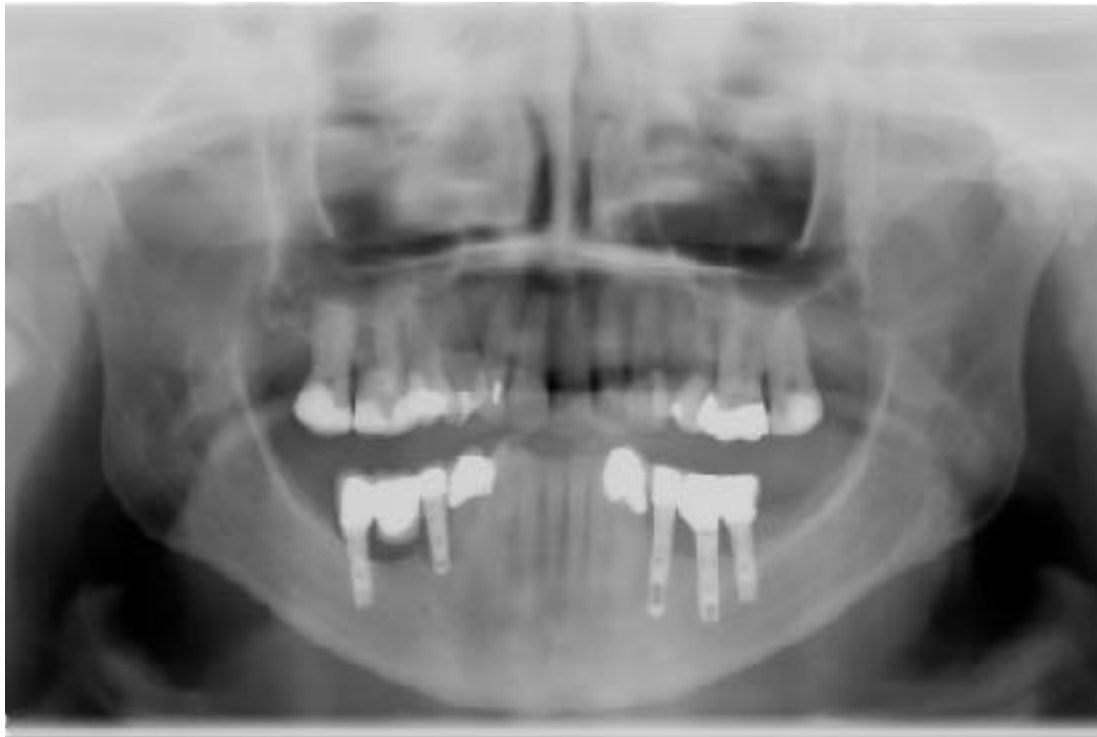

blue[®]m, for the protection of injured periodontal tissue

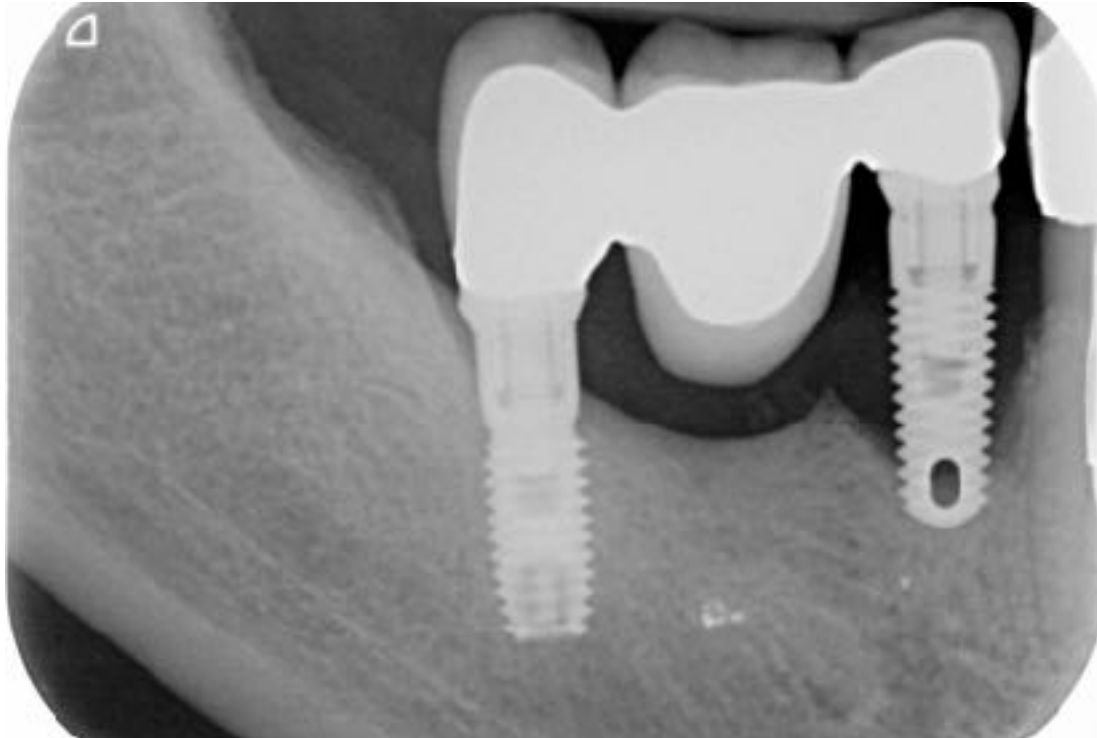
Peri-implantitis of the 4.5 : A 3 year follow -up



X-ray date: 30-06-2014

blue[®]m, for the protection of injured periodontal tissue

Peri-implantitis of the 4.5 : A 3 year follow -up



X-ray date: 21-08-2014

blue[®]m, for the protection of injured periodontal tissue

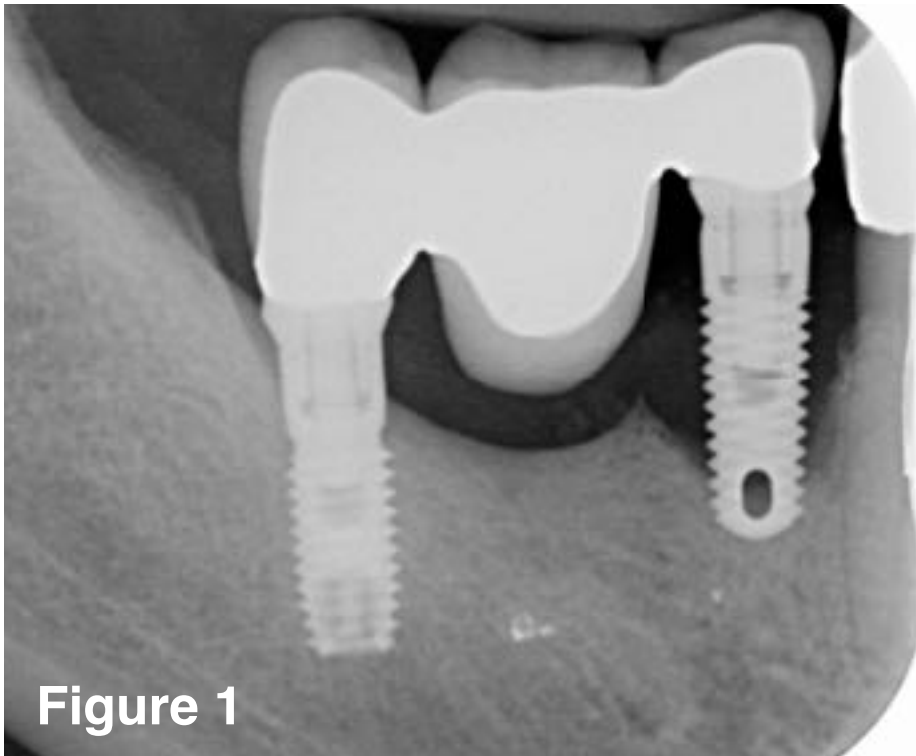


Figure 1

X-ray date: 21-08-2014

Anamnesis

- Female patient, smoker
- Patient had implant placement in 2010. Implant was placed in supraposition because of the location of the nervus mentalis and therefore was never completely subgingivally integrated in the bone
- DNA bacterial test showed a high concentration of PG
- Therapy: AB metronidazole 500mg 3x1p/d for 7 days in combination with flap surgery on the 45

blue[®]m, for the protection of injured periodontal tissue

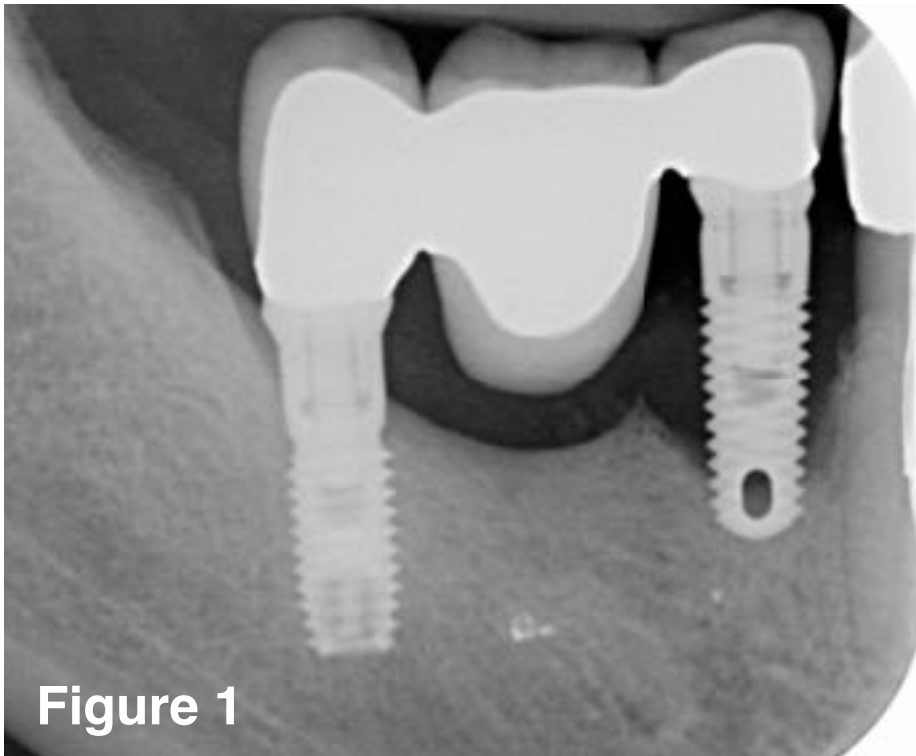


Figure 1

X-ray date: 21-08-2014

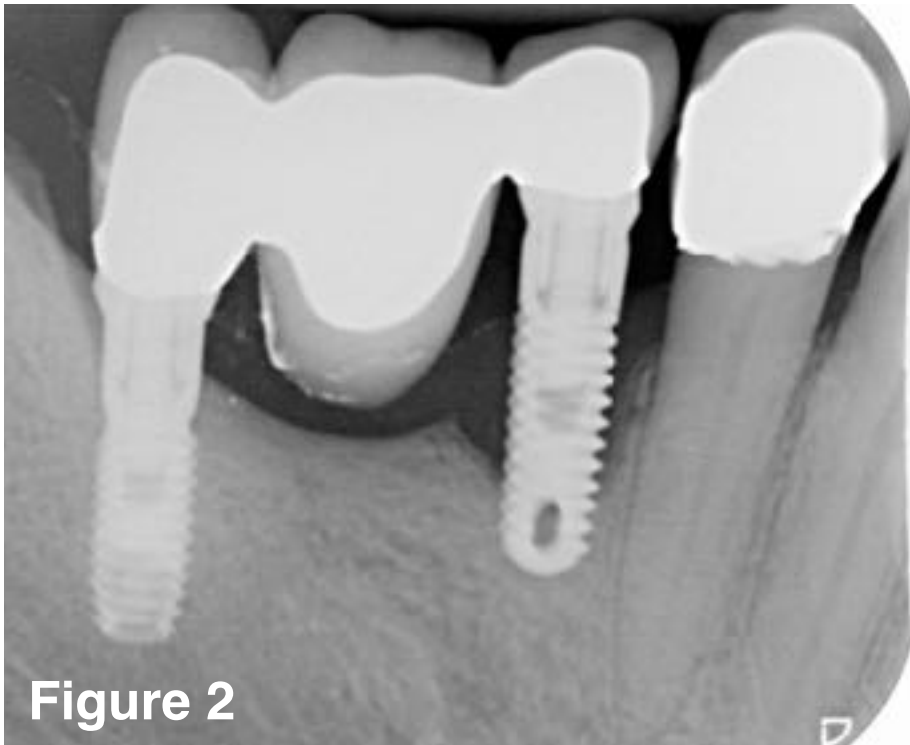
Postoperative Control 1 week later

- Good wound healing
- Removal of the stitches

Daily Instructions for the patient

- Apply blue[®]m oral gel at the 45 and 47 with interdental brushes 2 times daily
- Brush with blue[®]m toothpaste without fluoride

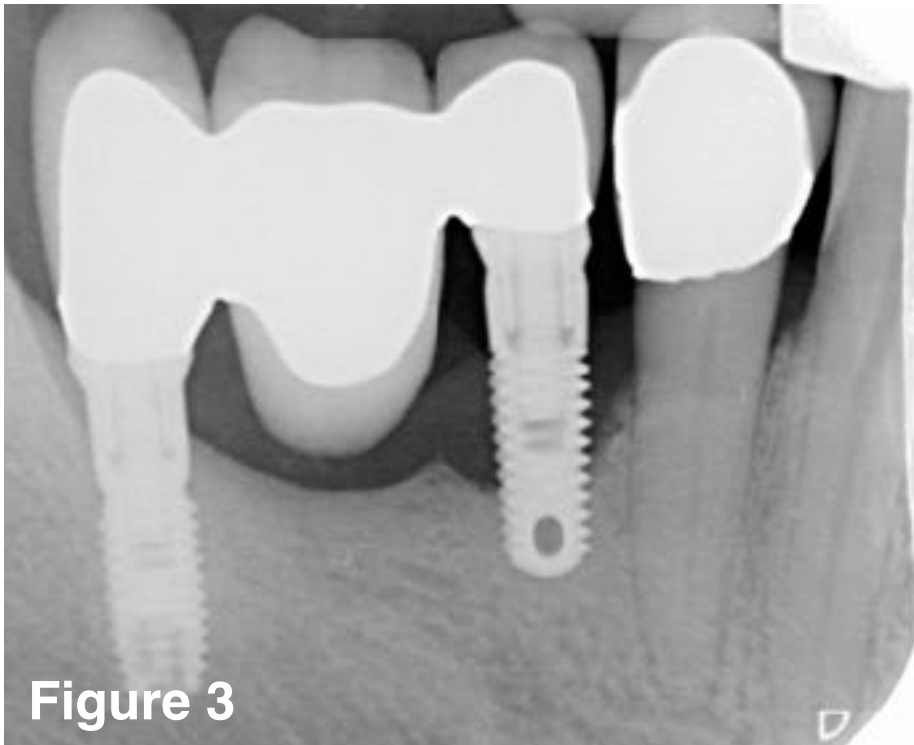
blue[®]m, for the protection of injured periodontal tissue



- Postoperative control after 4 months**
- Part of the implant is visible supra gingival
 - Patients oral hygiene is good
 - X-ray shows no further degeneration of bone tissue
 - No bleeding on probing

X-ray date: 15-12-2014

blue[®]m, for the protection of injured periodontal tissue

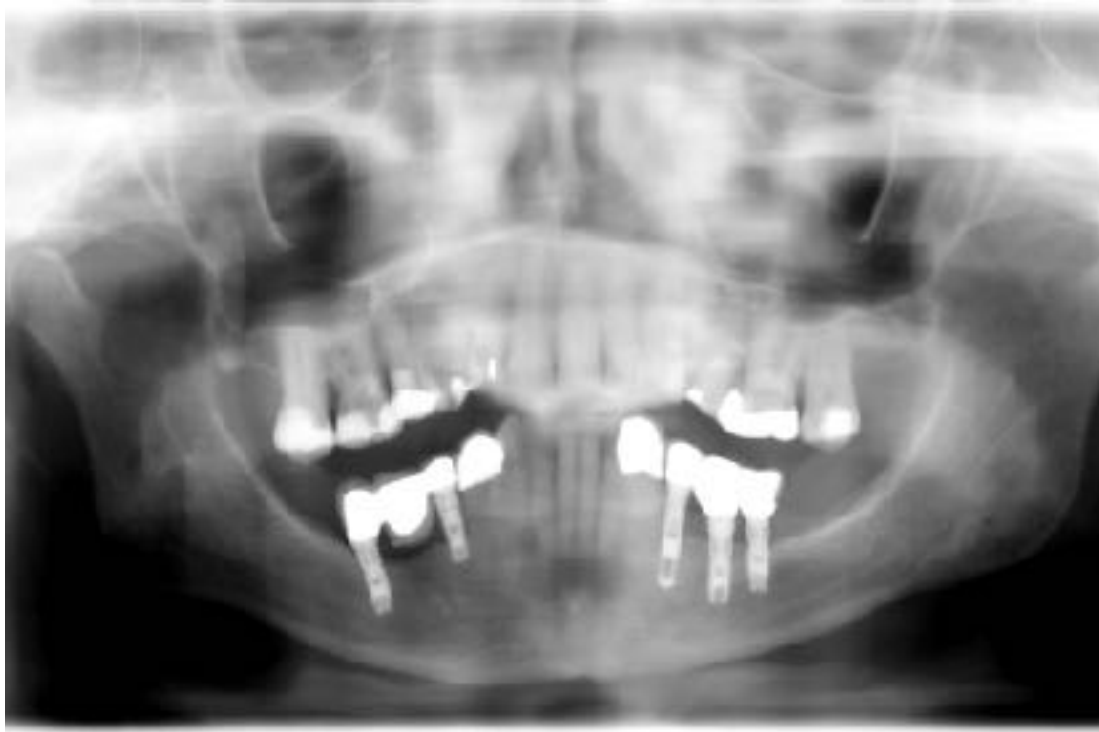

- Check up at the dentist almost 1 year later**
- X-ray shows good bone quality
 - Patient stopped smoking end of 2015
 - Patient still brushes with blue[®]m fluoride free toothpaste

X-ray date:17-06-2015

blue[®]m, for the protection of injured periodontal tissue

Peri-implantitis of the 4.5 : A 3 year follow -up



X-ray date: 19-12-2016

blue[®]m, for the protection of injured periodontal tissue

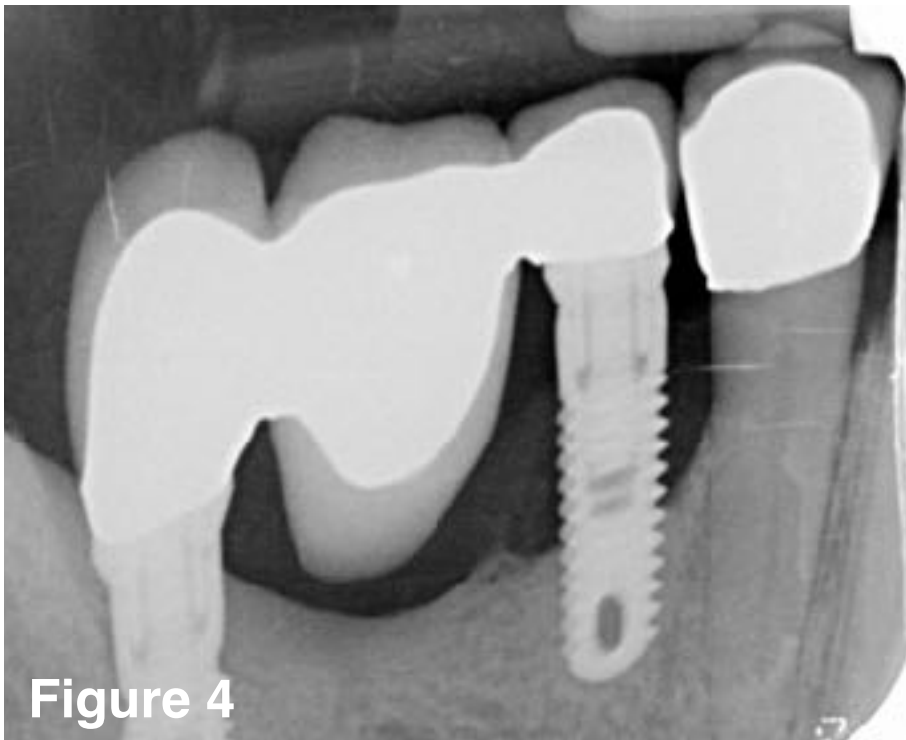


Figure 4

X-ray date: 27-06-2017

Check up at the dentist 2 years later

- X-ray bone quality looks even better
- 45 shows bleeding on probing because the implants screw is difficult to clean
- Patient keeps on brushing with blue[®]m fluoride free toothpaste and will start to apply blue[®]m oral gel with interdental brushes at the 45 again

blue[®]m, for the protection of injured periodontal tissue

The implant 45 shown on the X-Ray of 21-08-2014 (Figure 1) and on the X-Ray of 27-06-2017 (Figure 4)

