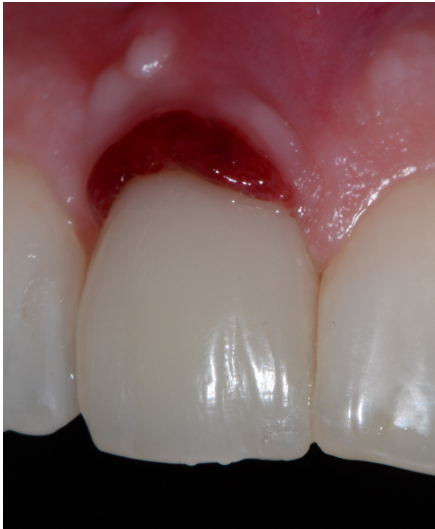

BlueM, for the protection of injured periodontal tissue

## *Peri-implantitis 1.1*

October 2016: Curitiba Brazil



## BlueM, for the protection of injured periodontal tissue

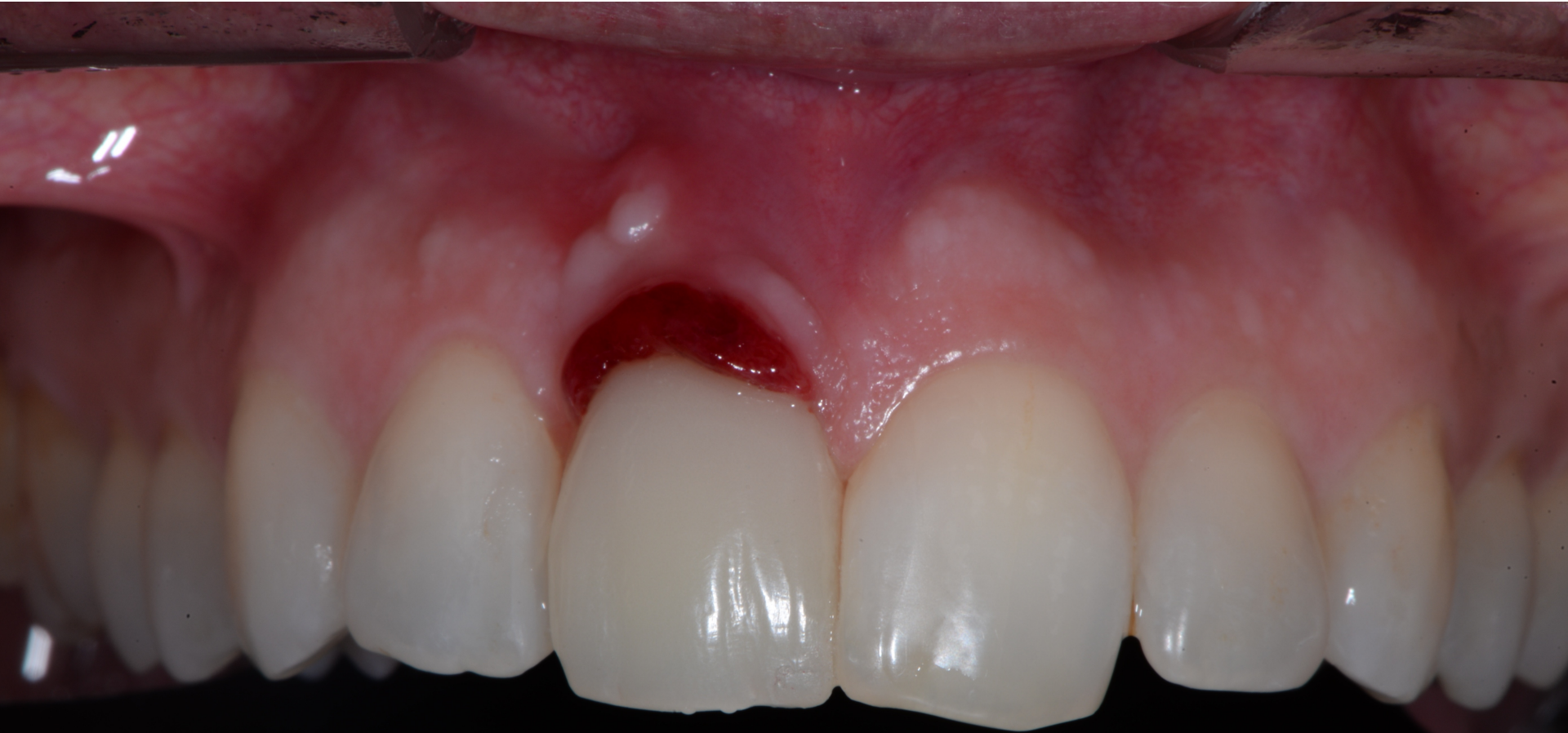Prof. Dr. Me. ANDRÉ LUIS ZÉTOLA , Curitiba Brazil.

Oral and maxillofacial surgeon specialised in maxillofacial trauma.



- Dr. in Implantology, UFSC (Federal University of Santa Catarina);
- Master in Head & Neck surgery, Heliópolis Institute São Paulo;
- Specialist Maxillo-Facial Surgery, UERJ (Universidade do Estado do Rio de Janeiro);
- Post Graduate Buco Maxillo Facial & Implantology Surgery, Northwestern University Chicago;
- Former President Brazilian Academy of Osseointegration ABROSS;
- Coordinator specialization course in implantology of SOEPAR( Association of Dentology Paraná);
- His experience in dentistry has emphasis on orthodontics and operates mainly in the following themes: desmoplastic fibroma maxillofacial surgery, traumatology.

BlueM, for the protection of injured periodontal tissue



**Figure 1 Pre-op**

## BlueM, for the protection of injured periodontal tissue

### Peri-implantitis 1.1

*Implant type: Straumann bone level SLA 4.1*

- Female patient. Patient had implant placement just after extraction with Bio Oss grafting and primary closure. The healing period was prosperous (app. 3 months). After the three months the healing abutment was removed and the provisional prosthesis was installed. Two months later the patient came with a peri-implantitis and bleeding on probing. On the CT-SCAN exam was observed that the provisional abutment height was too low; less than a 0,5 millimeter. Therefore a platform switch concept was suggested. The abutment width was trimmed as well. BlueM mouthwash was used to clean the locally around the implant and then BlueM oral gel was applied on the implant sulcus and components. In the following days BlueM mouthwash has been prescribed and BlueM oral gel 3 times daily.

## BlueM, for the protection of injured periodontal tissue

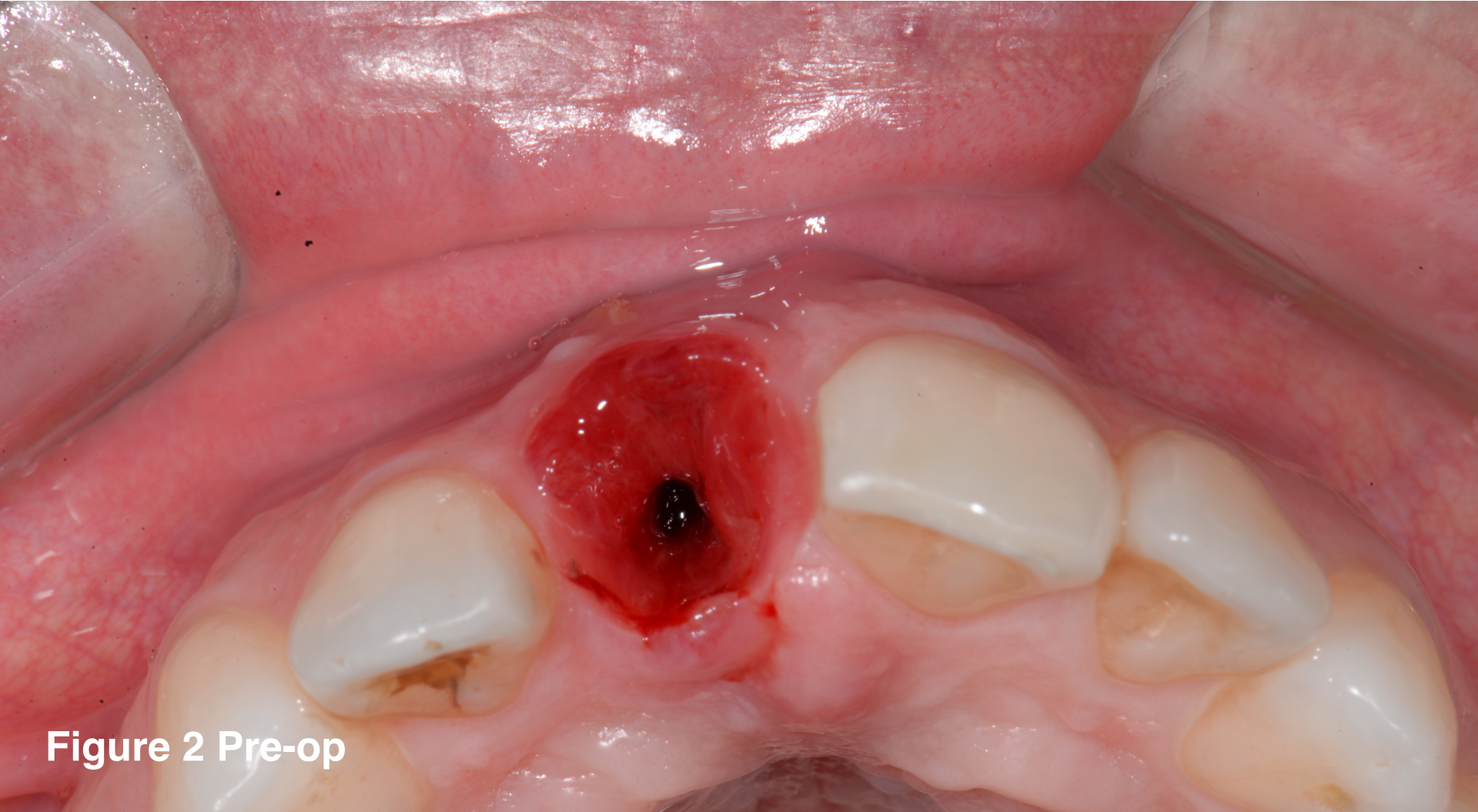

Figure 2 Pre-op

BlueM, for the protection of injured periodontal tissue

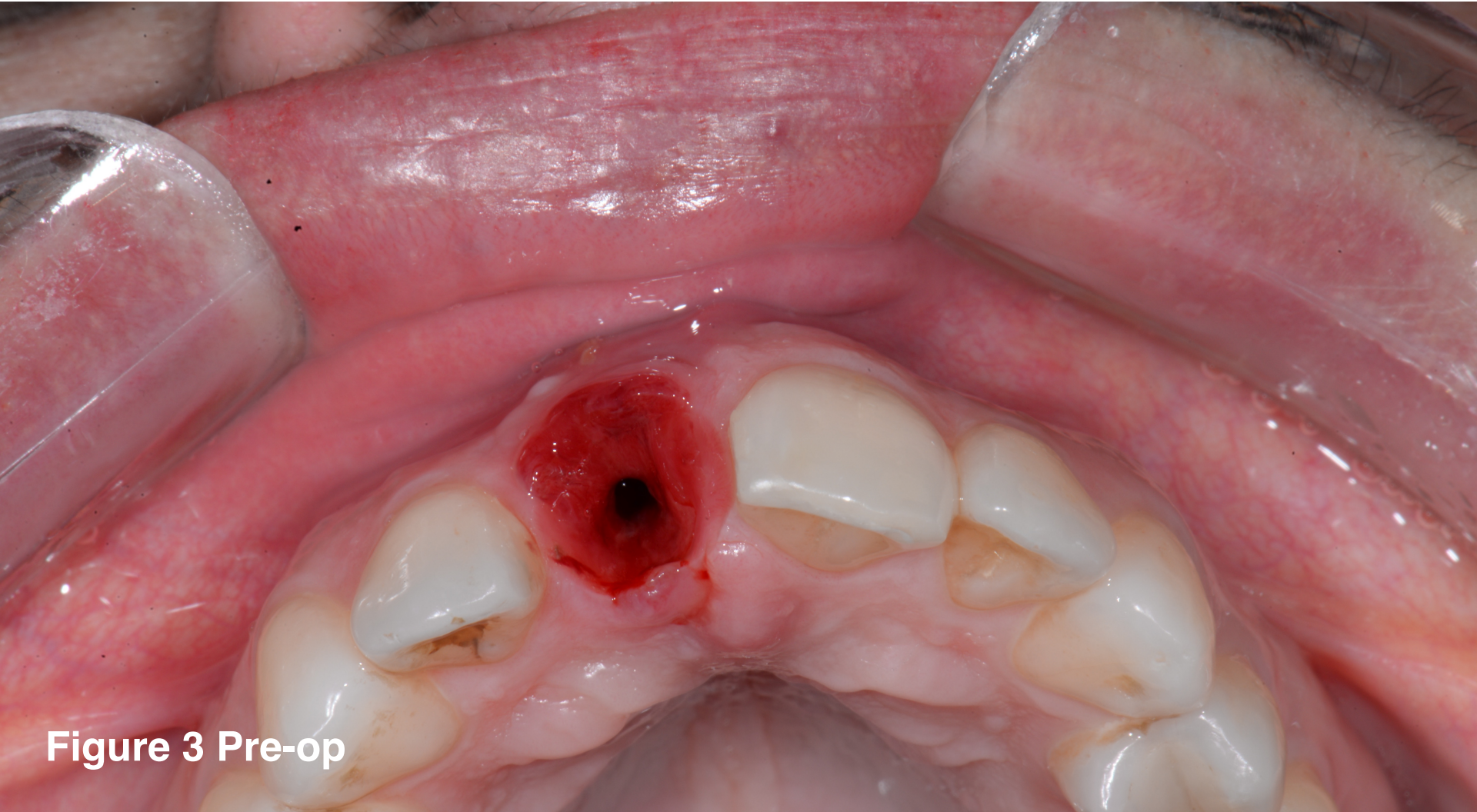
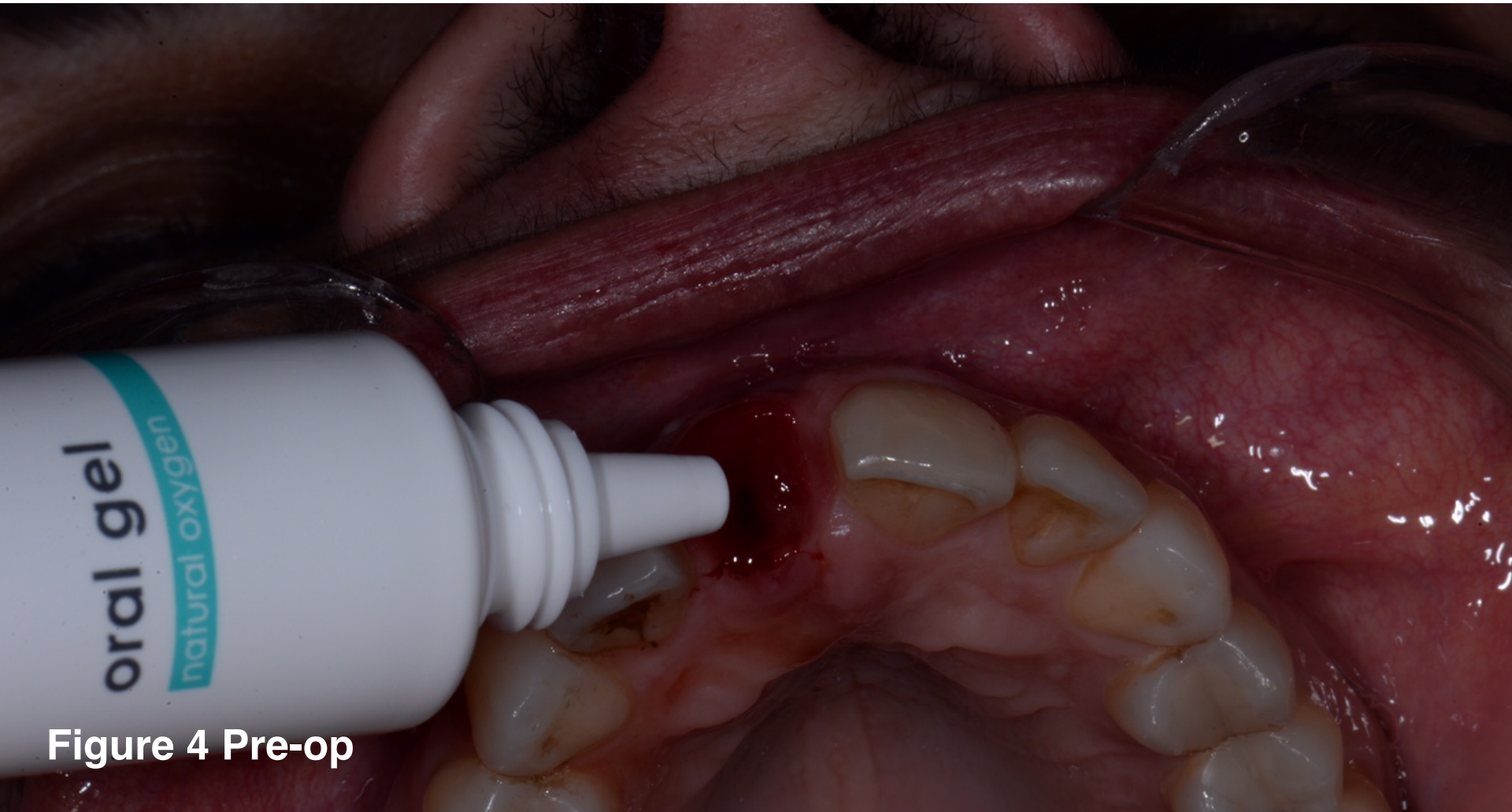


Figure 3 Pre-op

## BlueM, for the protection of injured periodontal tissue

- Protocol followed:
  - \* 3x daily rinse for one minute with BlueM mouthwash.
  - \* 3x daily apply BlueM oral gel.

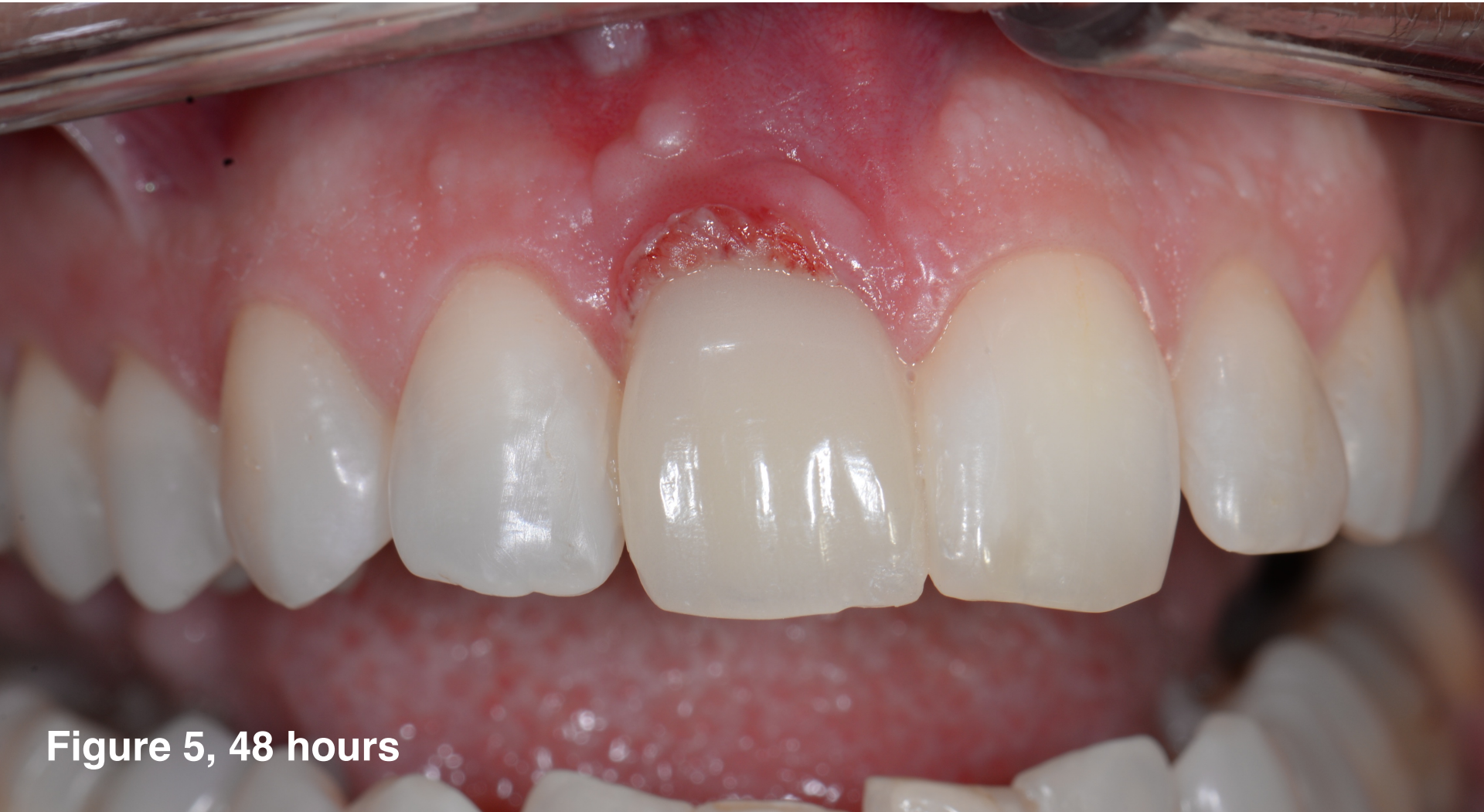## BlueM, for the protection of injured periodontal tissue



**Figure 4 Pre-op**

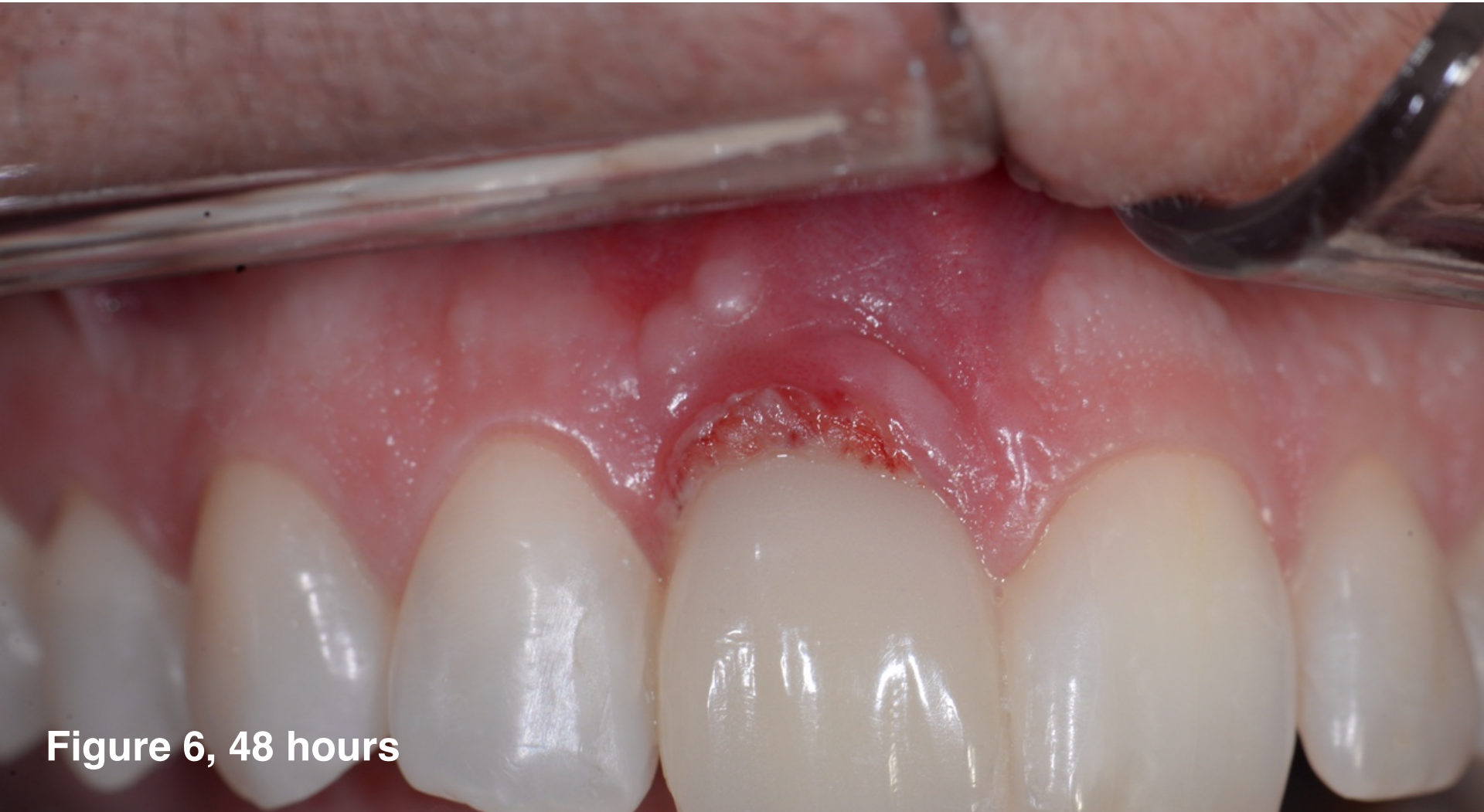

BlueM, for the protection of injured periodontal tissue



**Figure 5, 48 hours**

BlueM, for the protection of injured periodontal tissue

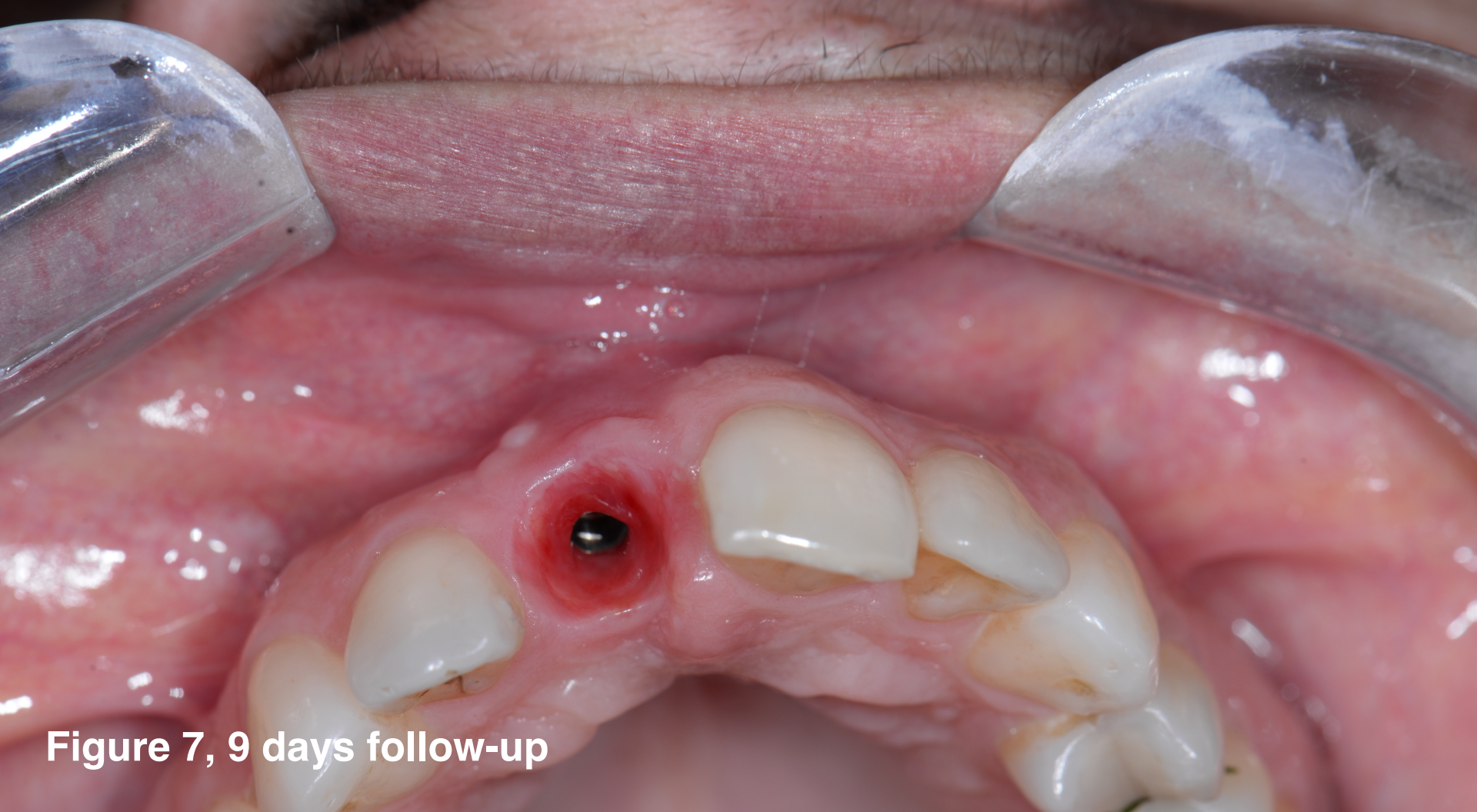


**Figure 6, 48 hours**

## BlueM, for the protection of injured periodontal tissue

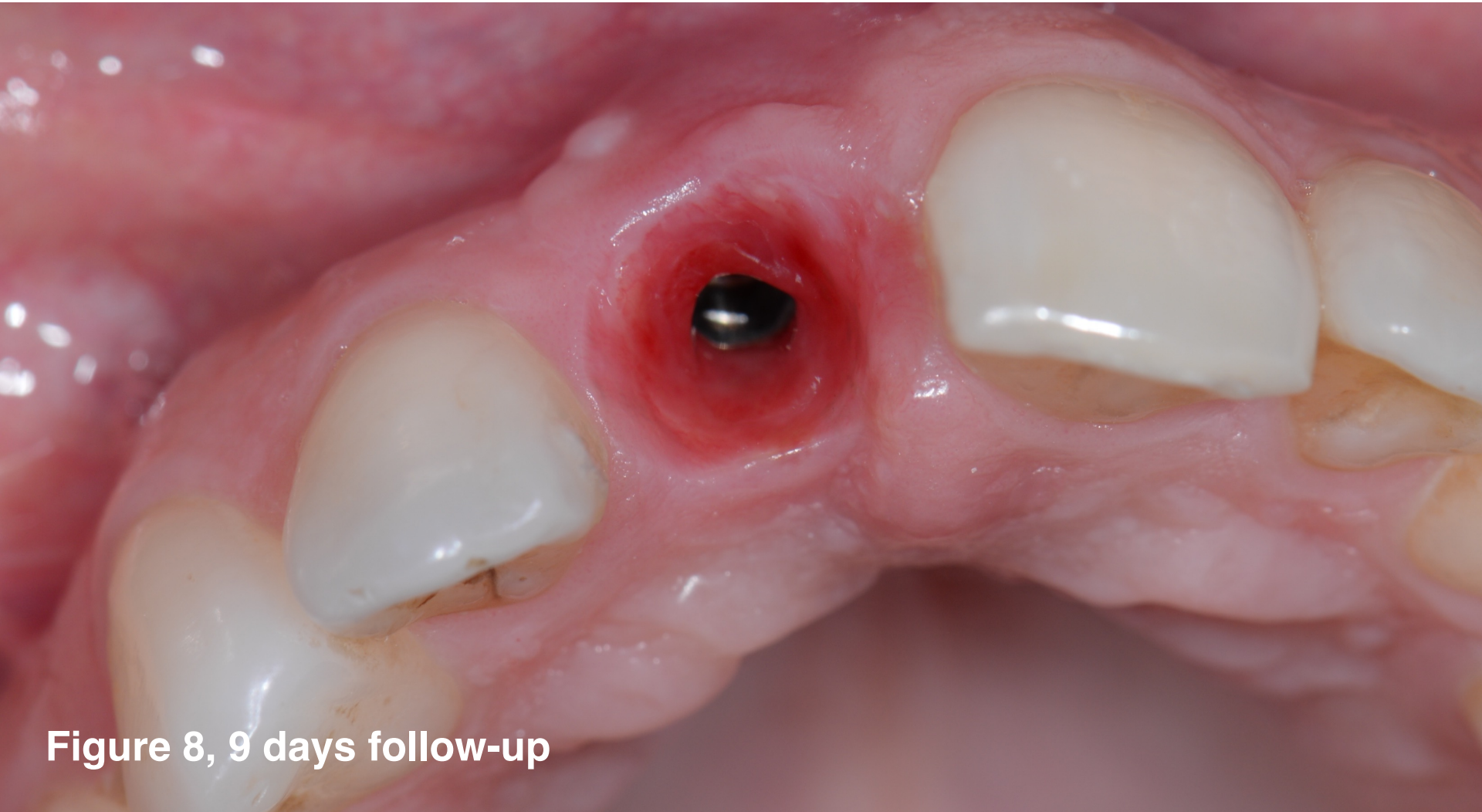
- After 9 days of using BlueM mouthwash 3x per day and BlueM oral gel 3x per day.

BlueM, for the protection of injured periodontal tissue



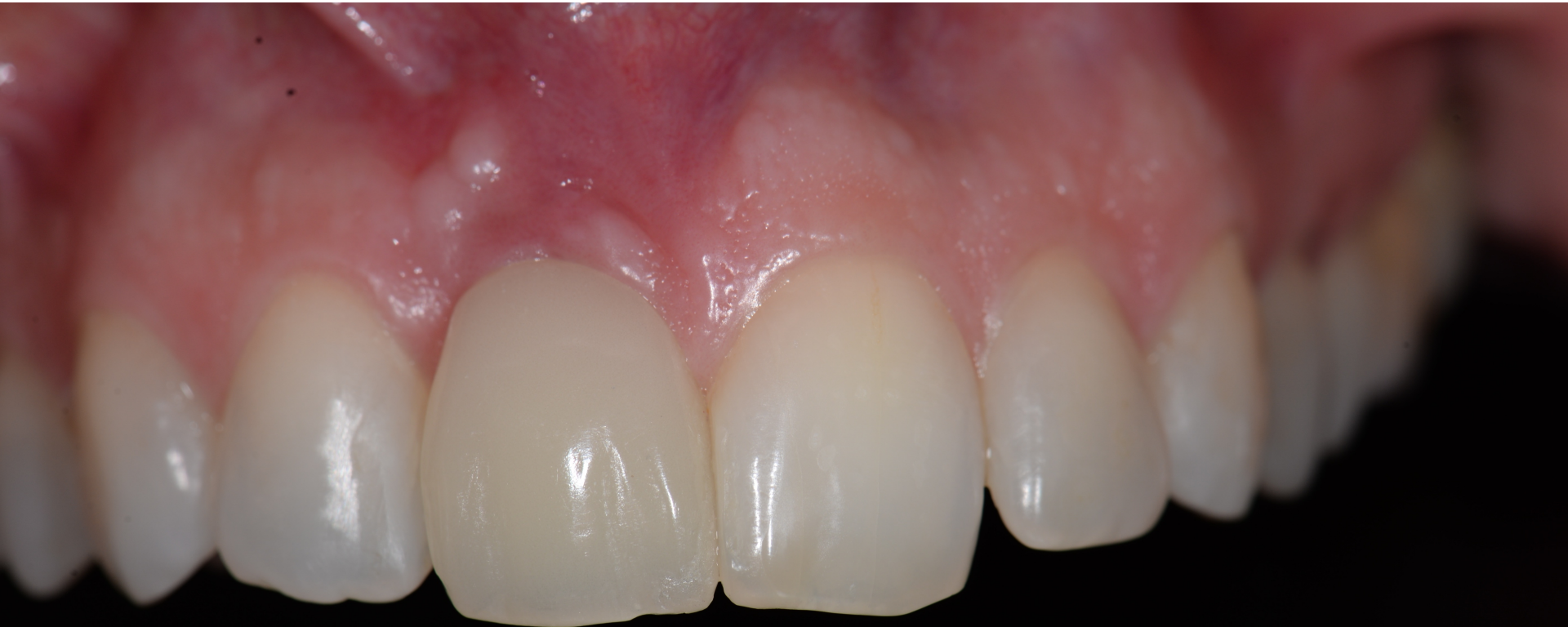**Figure 7, 9 days follow-up**

BlueM, for the protection of injured periodontal tissue



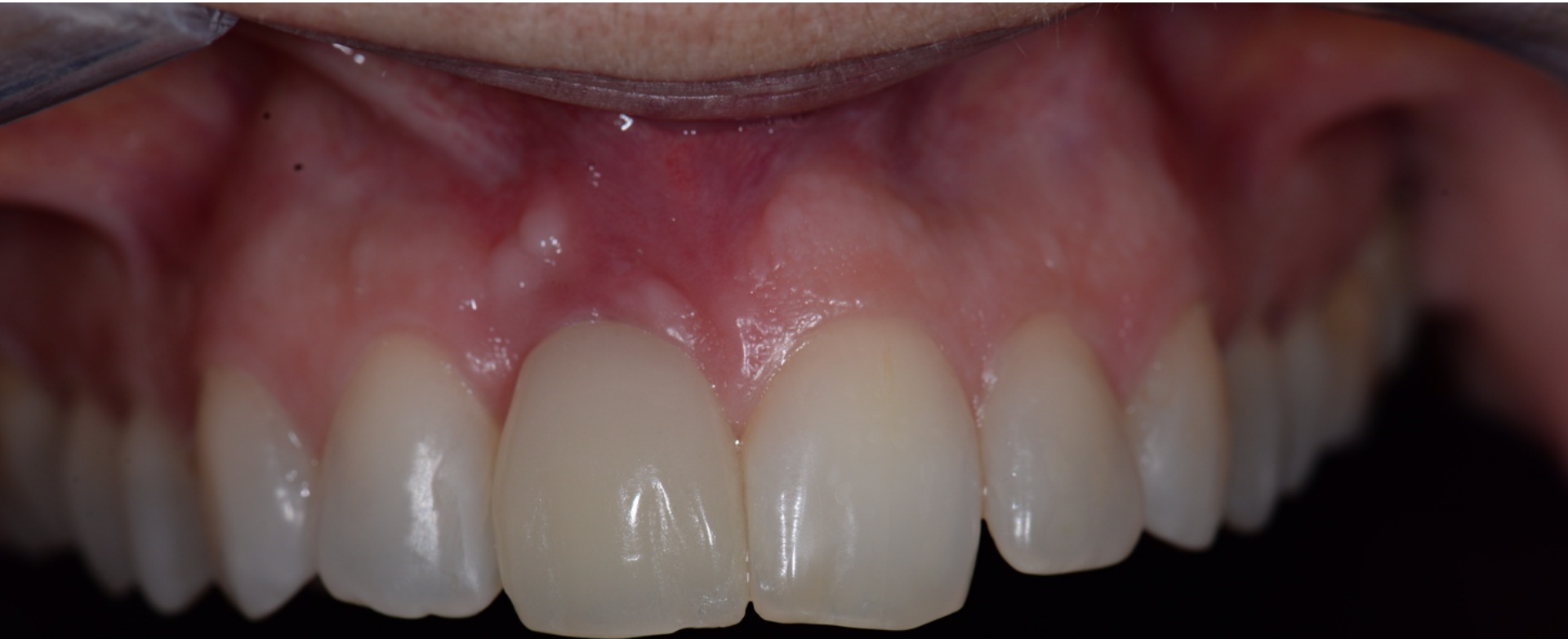**Figure 8, 9 days follow-up**

BlueM, for the protection of injured periodontal tissue



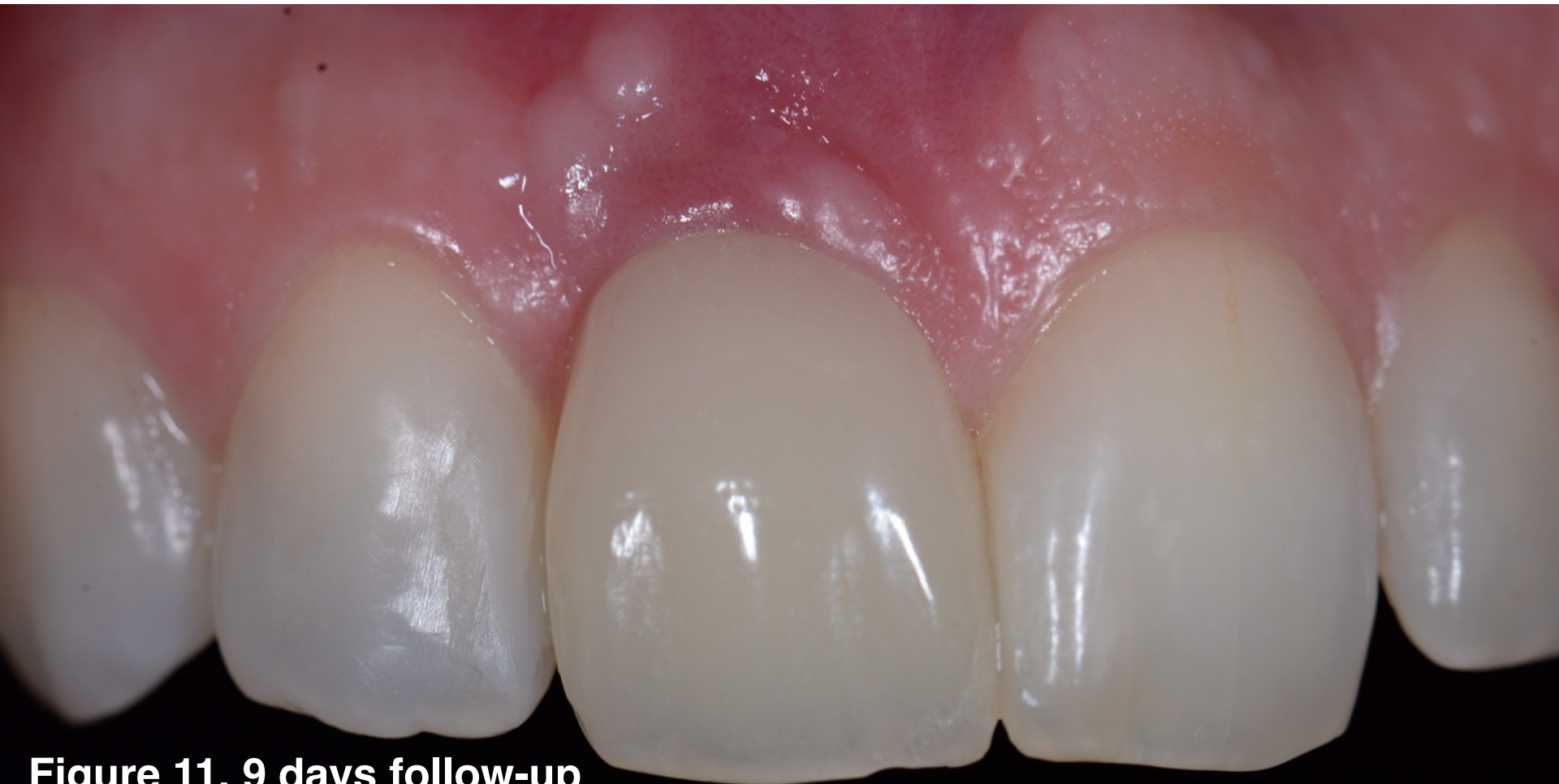**Figure 9, 9 days follow-up**

BlueM, for the protection of injured periodontal tissue



**Figure 10, 9 days follow-up**

BlueM, for the protection of injured periodontal tissue



**Figure 11, 9 days follow-up**



## BlueM, for the protection of injured periodontal tissue

